

**Arterial Lower Limb Duplex**Examined **30/01/2019 14:48**

Page 1 of 2

**R Chandrasekar**

Reference

Accession **CR-18-0067234**

Patient **Noreen Godsall**  
D.O.B. **20/06/1933**

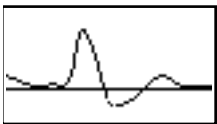
NHS No **616 101 6087**  
Patient Ref **3153463**

Reason Lymphoedema  
Outcome Stenosis severe

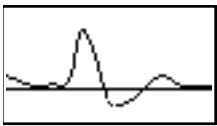
**Right**

110

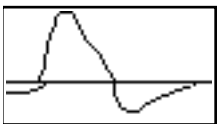1.00



Good



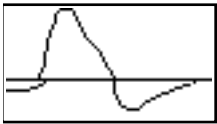Good



Good

120

1.09



Good

**Brachial****Common Femoral****High Thigh****Low Thigh****Popliteal****High Calf****Peroneal****Anterior Tibial****Posterior Tibial****Dorsalis Pedis****Toe Pressure****Post Exercise****Left**

Good

Good

Good

Good

110

1.00

**Notes****BILATERAL LOWER LIMB ARTERIAL DUPLEX****RIGHT:**

CFA, PFA origin, SFA and PopA - patent with good bi/triphasic waveforms, PSV 64-105cm/s.

TPT is patent. 3 run-off origins noted.

ATA and PTA - patent along length, good biphasic waveforms at the ankle, PSV 64-68cm/s.

**LEFT:**Assessed by **Sharifa Kiyegga**

Printed on 30/01/2019 at 3:59 pm

Checked by \_\_\_\_\_



Patient **Noreen Godsall**  
D.O.B. **20/06/1933**

NHS No **616 101 6087**  
Patient Ref **3153463**

CFA, PFA origin, SFA and PopA - patent, good bi/triphasic waveforms, PSV 45-109cm/s.  
TPT is patent. A 1.2cm severe stenosis identified proximally/ distal popliteal artery, velocities increase from PSV 66cm/s to PSV 275cm/s.

ATA and PTA - patent along length, triphasic waveforms at the ankle, cm/s.

Right resting ABPI's good (1.09)

Left resting ABPI is within normal limits (1.0)- patient unable to perform, adequate exercise challenge.

